

JCO INTERVIEWS

Dr. Ravindra Nanda on Orthodontic Mechanics

DR. KEIM What changes in opinion have you noticed with respect to the application of orthopedic forces using protraction headgear since your landmark papers in the late '70s and early '80s¹⁻³?

DR. NANDA Orthopedic forces, especially those related to the protraction headgear, are often not applied correctly; thus, the results are often unsatisfactory. At the same time, over the years our perception regarding its limitations has matured. To begin with, it is difficult to determine the inherent genetic potential as well as the timing of growth in a particular patient. Besides, the force applied from most of the protraction headgear designs is usually directed below the center of resistance (CR) of the maxilla, resulting in the

opening of the mandibular plane angle. This increases the vertical dimension and swings the mandible back, which gives an appearance of improved facial profile, and severely limits its application in a moderate-to-high-angle patient.

DR. KEIM Is it necessary to counteract the extrusive forces that occur as side effects in maxillary protraction?

DR. NANDA Yes, I think that is one of the most important aspects of protraction headgear therapy. In fact, it is the key between success and failure with this appliance. Since the early '80s, I have recommended use of a headgear bow distally inserted into molar tubes.² The outer bow can be bent up so that it is above the CR of the maxilla. Applying a force from this point will generate a clockwise moment on the dentition. Additionally, a chin-cup appliance can also be used throughout treatment, especially in high-angle patients. It helps in counteracting the downward and backward rotation of the mandible.

DR. KEIM What histologic changes do you note in the sutures as a result of protraction?

DR. NANDA Sutures react in a similar fashion as the periodontal ligament at the cellular level. Just going by nature of the force being exerted (protraction—moving the maxilla away from the cranium), one is compelled to assume that bone will deposit at the interface of all midfacial sutures. However, it is important to realize that, unlike the periodontal ligament, the sutural articulations are more complicated and tortuous in anatomy. They are serrated, convoluted, and twisted. Take, for



Dr. Nanda



Dr. Keim

Dr. Nanda is an Associate Editor of the *Journal of Clinical Orthodontics* and Professor and Head, Department of Craniofacial Sciences, Alumni Endowed Chair, School of Dental Medicine, University of Connecticut, 263 Farmington Ave., Farmington, CT 06030; nanda@nso.uconn.edu. He presented the John Valentine Mershon Memorial Lecture at the 2009 AAO annual session in Boston. Dr. Keim is Editor of the *Journal of Clinical Orthodontics*.

example, the zygomaticomaxillary suture. My studies on rhesus monkeys clearly showed that due to the nature of these sutures, areas of both resorption and bone deposition can exist simultaneously in a particular zone of the suture.^{1,3} Also, as children grow, the interdigitations of midfacial sutures become more complex, thereby making it more difficult to advance the maxilla after the age of 9-10 years.

DR. KEIM What are the appropriate force levels and points of force application for protraction headgear treatment of Class III malocclusions?

DR. NANDA This is one area of craniofacial orthopedics that has received very little attention in terms of well-designed prospective randomized clinical trials. Here are some of the guidelines that I have used. Children in the 6-to-9 age group have simple articulations of their sutures and hence require relatively light orthopedic forces, on the order of 200-250g per side. With increasing complexity of the sutures, force levels have to be increased to cause effective separation and new bone formation. Therefore, in the 8-to-10-year age group I prefer 300-400g per side, and in children 12 years and older, 500g per side.

Point of force application is very critical in the overall mechanics of a protraction headgear. Traditionally, the elastic pull from the outer bow does not allow a change of force application. Therefore, I prefer to use a distally inserted headgear with the outer bow bent up closer to the CR of the maxilla. Studies by Tanne and colleagues have shown that the CR of the maxilla is located 15.8cm below the orbitale.⁴ As long as we know that our applied vector of force is in this area, we can strive for predictable mechanics.

DR. KEIM Do Class III malocclusions benefit from two-phase treatment?

DR. NANDA That's not a very easy question to answer. Personally, over the years I have had less experience in treating very young patients of 6 or 7. However, colleagues from Japan and Taiwan have shown that developing Class III malocclusions may benefit from a two-phase treatment. The

best age is probably 6-8 years, as patients are more cooperative and force levels are not very uncomfortable. I must mention here that success will never be 100%. A significant number of these patients will turn out to be full-blown Class III near the termination of active growth. However, advantages still outweigh disadvantages regardless of the final outcome, as a relatively good esthetic result during the formative years is very positive for the overall development of patients.

DR. KEIM What are your current views on chin-cup therapy?

DR. NANDA My perspective on chin-cup therapy and its effects is not very much different from that of Sugawara and Mitani.⁵ They have shown that if there is a Class III growth pattern (true mandibular prognathism), it will tend to reappear after active orthopedic intervention. In my experience, I have learned that one cannot be certain of the final outcome until growth is complete. Although the treatment effects appear positive during treatment and are successful in correcting the underlying skeletal discrepancy, long-term follow-up of many patients has shown a reversion to the original growth pattern.^{6,7}

DR. KEIM Do you feel that there are too many conclusions drawn in the literature from research based on short-term studies?

DR. NANDA I think short-term studies only give you an insight as to how an appliance or technique works on a patient for the time it is being used. The generalizations that are drawn from these studies should always be taken with a grain of salt. As I mentioned previously, the growth and retention effects on the outcome of the treatment are always missing from short-term studies. Hopefully, in the future we will get to see more prospective studies that have long-term follow-up protocols.

DR. KEIM Why is it important to control vertical development when performing rapid maxillary expansion (RME) in conjunction with face-mask therapy?

DR. NANDA The majority of RME patients have a long vertical dimension and minimal overbite. Palatal expansion usually shows two clinical effects: buccal tipping of the posterior teeth, which places the lingual cusp down; and separation of the maxilla with the center of rotation around the nasal suture, resulting in the tipping of the two halves. The latter effect is critical, as it relates to the age of the patient—i.e., the older the patient, the more tipping there will be. The overall effect is clockwise rotation of the mandible and a resulting open bite.

DR. KEIM What kind of RME do you prefer?

DR. NANDA We always talk about using “light” and “gentle” forces in orthodontics. But with RME, force magnitude can easily be called “violent” in nature. In the early '80s, using laser holography, we showed that RME affects all cranial bones. This effect is more extreme when a suture does not open easily, as the overall force then accumulates. This is one of the reasons I do not believe in or recommend RME for patients who do not have skeletal crossbites.

When I use RME, after the desired amount of expansion is obtained, I prefer to leave the Hyrax-type expander in for at least eight to 10 months, providing enough time for the new bone to mature and for neuromuscular adaptation. I do not use or recommend bonded RME appliances. Bonded expanders cannot be left in the mouth for a long period of time, and I do not like the type of sutural opening they deliver. My fixed expander uses only molar bands and wires extending up to the canines. After the expansion, I cut the wires if expansion in the canine area is not needed. In any case, the majority of RME patients show more sutural opening in the canine area.

DR. KEIM Is there such a thing as an optimal bracket system?

DR. NANDA In an ideal situation, every patient is unique and hence will have his or her own distinct arrangement of teeth. From this standpoint, my answer to your question is negative. Most prescriptions have predetermined average torque/tip

and in/out prescriptions incorporated in their system, so they cannot boast of being optimal for every patient. Currently, there are some products in the market that are trying to address this problem; however, they are slightly complicated from a time-and-money standpoint. In the future, maybe cone-beam computed tomography (CBCT) can be incorporated for an accurate three-dimensional estimation of the teeth in the oral cavity. All things considered, the added cost and effort might not yield any clinically significant results compared to what we have now.

DR. KEIM What do you see as the pros and cons of self-ligating brackets as opposed to regular brackets?

DR. NANDA I do not see any cons here. I feel the advantages are primarily related to reduction in chairtime, longer appointment intervals, and maybe slightly faster alignment of teeth. Also, they are more hygienic. Some studies have shown a reduction in overall treatment time. I switched to Carriere* self-ligating brackets about three years ago, and I do notice a decrease in treatment time of nonextraction patients. The rest of the stuff we hear about self-ligating brackets' doing magic is all commercial noise.

DR. KEIM What should one look for in a self-ligating bracket?

DR. NANDA Self-ligating brackets have mechanical parts, like doors and clips, which have to open and close for changing wires or for making other adjustments. It is important that these parts function adequately throughout treatment. It can get very annoying and time-consuming if a door or a clip malfunctions or breaks. Another important aspect is the choice between an active and a passive bracket. I personally prefer a passive system with higher torque, as it allows me to determine the amount of slot-wire relationship by changing the wire dimensions, especially during the finishing stage. But then, all this is a matter of personal

*Registered trademark of Ortho Organizers, Inc., 1822 Aston Ave., Carlsbad, CA 92008; www.orthoorganizers.com.

preference and familiarity with the system; in other words, there is a learning curve with every system out there in the market.

DR. KEIM Is there such a thing as a “frictionless” bracket?

DR. NANDA I think the concept of a “frictionless” bracket is a myth. It can only be frictionless if there is no wire in the bracket! I have always believed in the concept of “friction on demand”. In other words, by changing the dimension of the wire based on the type and direction of tooth movement, we can increase or decrease the amount of friction. Important point: it’s mechanically impossible to do a majority of tooth movements without friction. Most of the time friction works in our favor.

DR. KEIM Could you elaborate on your concept of the “family of biomechanics”?

DR. NANDA There is no formal definition for the phrase “family of biomechanics”. It encompasses a set of biomechanical concepts that are critical in understanding the nuances of tooth movement in relation to the application of a well-defined force system and the resulting tooth movement. It includes terms like force, moment, differential force system, point of force application, center of rotation, center of resistance, etc.

DR. KEIM How do you define “differential forces” and “differential moments”?

DR. NANDA Both these concepts are used to preserve or augment anchorage for moving teeth. The term “differential forces” is used to describe a biomechanical design of a force system which, by the way of its application, is able to distribute the reciprocal forces over significantly different root areas with the objective of eliciting a differential response. A good example is a combination of closing loops for upper incisor retraction along with the application of Class II elastics, thereby increasing the retraction force as compared to the anterior force felt by the upper molars.

On the other hand, differential moments can

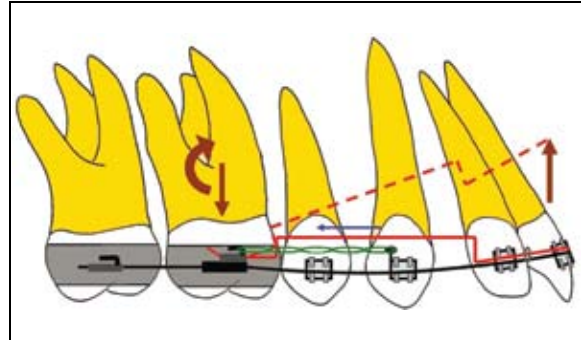


Fig. 1 Concept of differential moments applied to augment anchorage value of molar for cuspid retraction.

be created by placing a bend on a wire between two brackets or groups of teeth. The bracket or tooth closer to the bend will have a greater moment, and this can in many ways be used to augment anchorage. For example, an intrusion arch creates a greater moment on the molar, thereby neutralizing the anterior component of retraction force if used as a piggyback wire with straightwire cuspid or anterior retraction (Fig. 1).

DR. KEIM Do orthodontists routinely use too much or too little force?

DR. NANDA This is a good question. First, we still do not precisely know the smallest force that will give an optimal tooth movement. I feel the force values currently being used for a particular type of tooth movement end up on the excessive side. The problem is that the force magnitude not only varies by the type of tooth movement required—for example, torquing as opposed to simple tipping—but also with the stage of tooth movement. The force required to initiate a tooth movement is substantially different from that required to sustain the same movement. Canine retraction might require an initial force of 200-250g, but even a 75g force will sustain it. Thus, in many techniques, if a retraction loop is reactivated at each visit, the force values are raised to initial force level, thereby applying an unnecessarily high force.

DR. KEIM You mentioned in your Mershon lec-

ture that “round-tripping” in orthodontics is very annoying to you.

DR. NANDA Round-tripping is not only annoying, but also a very non-biological tooth movement. It implies that the crowns or roots of teeth have moved in a direction in which they were not supposed to go. For example, anterior tooth retraction should ideally show either translation or controlled tipping. However, due to a simple force being directed below the CR, uncontrolled tipping occurs, which necessitates root uprighting, which was never part of the original malocclusion. Such an approach not only increases the overall treatment time, but causes deleterious effects on the roots and periodontium. In recent years, there has been much emphasis on reducing treatment time. The easiest way to achieve that is, perhaps, efficient tooth movement to the desired location.

DR. KEIM If you consider RME to be a “violent” tooth movement, what about molar distalization?

DR. NANDA Any time we enter a force magnitude in the realm of several hundred pounds, we are not only causing localized changes, but also affecting the neuromuscular system of the whole region. The popularity of molar distalization has always been an intriguing concept to me. I think ours is the only medical or dental specialty in which, in order to improve a condition, we first increase the intensity of malocclusion in the area that already needs correction. In distalization, we start with a malocclusion that shows a Class II molar and canine relation and increased overjet; after distalization, we further worsen the overjet and the canine relation before improving it. This not only increases the overall treatment time, but also creates an environment where unwanted and undesirable forces are being used on the periodontium. My personal feeling is that with the increased popularity of temporary anchorage devices (TADs), molar distalization will see fewer side effects.

DR. KEIM Do you predict that the use of TADs will fundamentally change biomechanics?

DR. NANDA I do not think so. The “fundamen-

tals” of biomechanics have nothing to do with skeletal anchorage. TADs are just devices that provide very high anchorage in most situations to move teeth in a more predictable manner. To attain success with implant-based orthodontics, a good knowledge of biomechanics is still important.

DR. KEIM Some orthodontists claim that TADs are being overused. Do you agree with that?

DR. NANDA Every new innovation in orthodontics had its time of extensive usage. In many ways this is good, because it means the device is being evaluated and used by many orthodontists. I think TADs are best suited only when we want to do group movement of teeth or intrusion or protraction of the molars, and in patients with multiple missing teeth. Any dental movement beyond these can be accomplished by conventional anchorage devices and techniques. I feel right now we are at the end of the commercialization phase, and once orthodontists become more familiar with the application of TADs, we are going to witness more judicious usage.

DR. KEIM Why do you find the term “straight-wire” confusing?

DR. NANDA The only time I can justify the term “straightwire” is when the brackets are completely aligned or when the wire is in the manufacturer’s packet—in both cases, the wire is straight! When we begin treatment, a straight wire never looks straight in the mouth, but reflects the malocclusion.

DR. KEIM Can you intrude teeth with straight-wire mechanics?

DR. NANDA A simple and straightforward answer is *no*. A straight wire without any bends is capable of only three things: expansion of the arch, extrusion of posterior teeth, and flaring of teeth. For intrusive forces, one must put in specific intrusion mechanics. Straightwire is very good for simple orthodontic malocclusions, but when we confront patients with midline problems, “gummy smiles”, anterior and posterior open bites, canted occlusal planes, and so on, we need sophisticated

mechanics to achieve desired results. Over the years, my team at the University of Connecticut has made significant efforts to simplify mechanics that can be used in a busy practice. We believe in light, long-acting forces that do not require frequent activations or wire changes and can control side effects.

DR. KEIM What do you mean by “fictional” occlusal planes vs. “anatomical” occlusal planes?

DR. NANDA A traditional occlusal plane—Downs, for example—bisects the overbite and occlusal contacts of the upper and lower molar. This occlusal plane does not take into consideration the long axis of the posterior teeth, vertical position of the upper and lower incisors, and any curve of Spee that might exist in the arch. A better way to determine the occlusal plane is to extend a line anteriorly, perpendicular to the long axis of a premolar from the initial point of molar contact.

DR. KEIM What is the role of archform?

DR. NANDA Appropriate archwire selection or fabrication is critical in maintaining the patient’s inherent dental archform. An archform is a reflection of the form of the upper and lower alveolar bone. In my early years at the University of Nymegen in the Netherlands, one of my instructors was Dr. Brodie, who was there as a Fulbright Scholar. He instilled in us the concept of alveolar apical base; his mantra was not to change an archform that was following the form of the alveolar apical base. I feel we are looking for potential relapse if we overexpand archforms.

We have to be very careful in the use of memory wires. As a rule, I use nickel titanium preformed archwires only to relieve crowding and align teeth. After this I primarily work with CNA* beta titanium wires, as they allow me to follow the patient’s archform, and I can also constrict, expand, and modify the wires to the individualized archform.

*Trademark of Ortho Organizers, Inc., 1822 Aston Ave., Carlsbad, CA 92008; www.orthoorganizers.com.

DR. KEIM Is the number of archwires used to treat a case a valid concern?

DR. NANDA Treatment philosophy should never be based on the number of archwires to treat a patient. I often hear during my travels internationally that an orthodontic course or lecture is teaching that treatment can be done with only three or four archwires. I think the amount of treatment time, as well as the number of archwires that will be required to achieve the desired goals, depends upon the needs of the particular case at hand.

DR. KEIM Do you think that wire bending has become a lost art in orthodontics?

DR. NANDA I do not feel this is entirely true. With preformed archwires and specialized loop wires and memory alloys, the need for wire bending has been considerably reduced. Nonetheless, a good finish quite often requires accurate wire bending. I feel our residency programs should not abandon a concentrated wire-bending course.

DR. KEIM What types of bends do you feel are important for orthodontic students to master?

DR. NANDA I feel all orthodontists should understand the consequences of placing a bend in the archwire. Burstone has very nicely described the “six geometries” involved when placing a bend between a two-bracket assembly and the resulting forces and moments on these brackets.^{8,9} Bends are simple to fabricate and master; however, it is important to understand the effects and side effects of the different geometries created by such bends.

DR. KEIM Why have you switched from T-loops to mushroom loops for space closure?

DR. NANDA We switched from T-loops to mushroom loops almost 15 years ago. We were interested in a more patient-friendly and user-friendly loop that would not impinge on the gingival tissues during insertion, activation, and space closure (deactivation). Using the preformed mushroom loops of different sizes makes their installation very quick and simple.

DR. KEIM How can we best implement biomechanics to enhance esthetic outcomes?

DR. NANDA Very few studies have tackled this issue. My colleague Flavio Uribe and I have shown, via case reports in this journal, the application of various simple mechanics to enhance esthetics with orthodontic treatment.^{10,11} We can intrude teeth to treat “gummy smiles”, use extrusion arches to extrude the incisors for smile improvement, place cantilevers to correct canted occlusal planes, and follow the “surgery first” approach to correct skeletal discrepancies. Using cookbook treatment or just straight wires will not help improve esthetics in an optimal fashion.

DR. KEIM Why do you advocate “surgery first” treatment plans for the orthognathic management of Class II cases?

DR. NANDA The “surgery first” approach has two distinct advantages over the conventional approach: first, there is an immediate correction of skeletal/hard tissue deformities, and second, it appears that it considerably reduces the effective time a patient spends in braces when compared to a conventional approach. We have completed a few cases in our division with great success. We are working with two other centers in this area and have published a couple of articles on the subject in JCO,^{12,13} with more in press.

DR. KEIM What side effects do you see when step bends are applied to treat open bites or closed bites?

DR. NANDA Step bends for an open bite produce equal and opposite forces on the anterior and posterior teeth, with the former experiencing extrusion and the latter intrusion—which is what we want. The problems here are the moments (Class I geometry⁸). Along with the forces, both these segments also experience moments that tend to bring the distal part of the posterior segment down and flare the incisors. Counteracting these moments is the key in treating such cases (Fig. 2).

DR. KEIM Can you elaborate on your use of

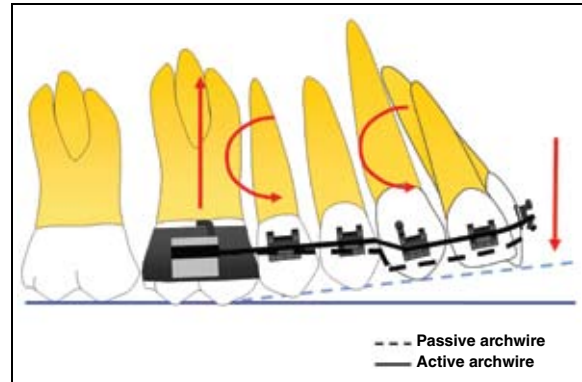


Fig. 2 Step bend (Class I geometry) creates moments that can worsen open-bite condition.

cantilevers to address vertical problems such as open bite or deep bite?

DR. NANDA We have covered answers to these questions in detail in several articles and in chapters in my three textbooks. Cantilevers create one-couple force systems, where the couple is produced at the posterior segment and a single force is acting on the anterior. An extrusion/intrusion arch is a perfect example; it greatly simplifies the correction of a deep bite or an open bite where controlled incisor movement is desired. However, it’s important to counteract the moment on the posterior segment with elastics (Fig. 3).

DR. KEIM Would you elaborate on your use of the intrusion arch for the lower incisors?

DR. NANDA An intrusion arch tied to anterior teeth or a segment can predictably achieve significant incisor intrusion. Lower incisor intrusion can be achieved by using an intrusion arch with an average force as low as 6-8g per tooth. Here, it is important to have a stable and strong posterior segment in order to withstand any side effects, although side effects are kept at a minimum due to the extremely low forces at the active site.

DR. KEIM When would you use intrusion arches in adult patients?

DR. NANDA For adult patients, intrusion arches

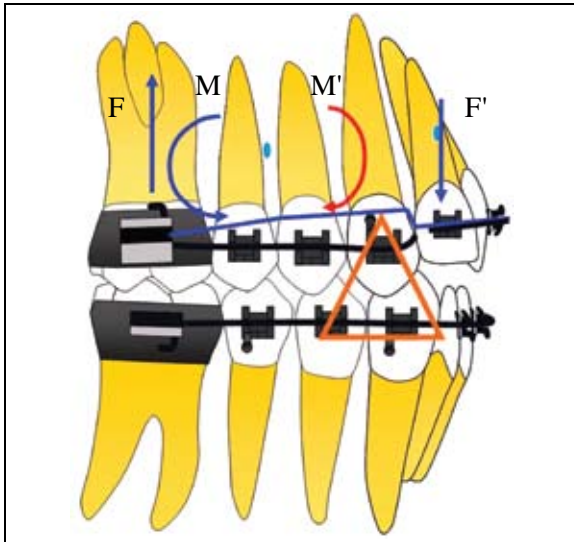


Fig. 3 Elastics (orange) can be effectively used to create moment (red arrow) to counteract moment (blue arrow) created by extrusion arch on posterior segment.

should be used in the lower arch to correct deep bite, unless the patient has retroclined upper incisors with a large amount of gingival display during speech and smiling.

DR. KEIM How much root resorption should be expected with incisor intrusion?

DR. NANDA A study by Costopoulos and Nanda showed that intrusion of the four maxillary incisors resulted in less than 1mm of resorption or root-tip blunting.¹⁴ Other studies have supported these findings.

DR. KEIM What labial soft-tissue changes should be expected with incisor retraction?

DR. NANDA Predicting soft-tissue changes with incisor retraction to some degree of accuracy is an arduous task. Most clinical studies have shown that the upper lip change with incisor retraction is around 3:1, while lower incisor retraction results in a 1:1 ratio. A similar change of the lower lip will result if the lower lip rests on the incisal edges of the upper teeth.

DR. KEIM Would you explain what you mean by “intraoral headgear”?

DR. NANDA I use the term “intraoral headgear” when intrusion arches are used during canine retraction with sliding/frictional mechanics. If an intrusion archwire is placed as a piggyback wire, the distal moment created on the molars is similar to that of a high-pull headgear used extraorally. This minimizes or eliminates the forward displacement of the molar due to the mesial (retraction) force. Additionally, the intrusive force on the incisors prevents the buckling of the anterior portion of the archwire, which can increase the overbite (Fig. 1).

DR. KEIM Do you use tongue cribs or spurs?

DR. NANDA I prefer tongue cribs. Cribs are more patient-friendly than spurs. In open-bite patients, due to the nature of the open bite, the tongue sits between the upper and lower teeth. Once the tongue interference is removed, there is spontaneous correction of the open bite due to the eruption of the teeth and the alveolar bone. I start the treatment of open-bite patients with only a tongue crib for five or six months, and I leave it in the mouth during active treatment for as long as it is feasible. Controlling oral habits before initiating orthodontic treatment is an integral part of treating various kinds of malocclusions. I often call this a “holistic” change, as I believe that a physiological and natural correction of malocclusion is far superior to that brought about by orthodontic forces.

DR. KEIM How are TADs applied in the treatment of open-bite cases?

DR. NANDA Recently, many studies have reported successful treatment results by employing miniplates and miniscrews for the treatment of open bites. Intrusion of the molars is the obvious choice with plates or screws; of course, we have to consider the esthetics of the patient before making this decision. Also, long-term retention studies are still lacking, and I am sure we will soon see them.

DR. KEIM When would you use bone plates

instead of miniscrews?

DR. NANDA Unlike a miniscrew, bone plates are usually held by three or more screws. This inherently makes bone plates more stable, especially when heavier forces are being used. Thus, bone plates can be very effective in delivering orthopedic-type forces. Sugawara and colleagues have shown very nicely that bone plates can deliver significantly large tooth movements.¹⁵

DR. KEIM Would you explain your concept of intraoral orthopedic movement of the midface?

DR. NANDA Historically, orthopedic protraction of the maxilla always had dental movement as a side effect, since we were anchoring on teeth. Nowadays, by using bone anchors, there exists a possibility of getting pure orthopedic movement. The two most accessible bones in the face next to the maxilla are the mandible and the zygoma. The mandible is a moving bone, and using it as an anchor with plates or miniscrews can cause them to fail due to constant loading and unloading forces. However, if we use the zygoma as an anchor, we can protract the maxilla with a constant force by pushing the maxilla against it. In our department we have tried some cases using intraoral orthopedic protraction. We have been somewhat successful, but you have to keep in mind that in these situations, growth is often working against you.

DR. KEIM How do you use cantilevers to treat impacted canines?

DR. NANDA As I mentioned previously, cantilevers create a one-couple force system in which the active unit experiences only a single force. Bending such a cantilever out of a CNA beta titanium wire ensures a low load/deflection, thereby providing physiological forces for a prolonged period and requiring hardly any reactivation throughout the eruption of the canine (Fig. 4).

DR. KEIM You co-wrote a great article for our 40th-anniversary issue on genetically driven treatment plans.¹⁶ What developments have you seen in

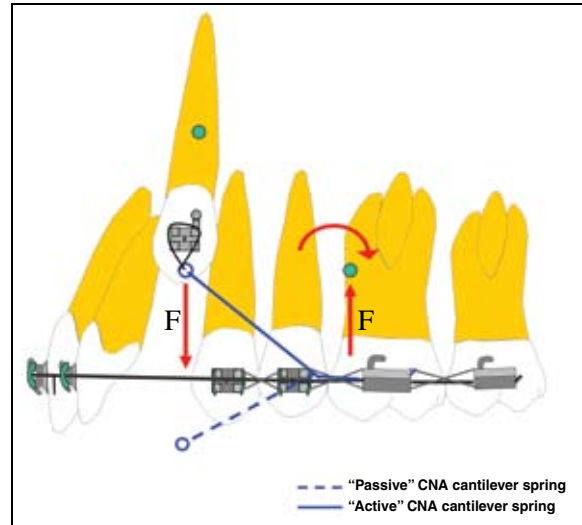


Fig. 4 One-couple cantilever force system for extrusion of impacted canine.

this field over the last few years?

DR. NANDA Orthodontics, similar to other medical specialities, has seen an explosion in the discovery of genes and polymorphisms associated with clinical anomalies and diseases. For example, in the last few years there has been a genetic association found in humans for root resorption, failure of tooth eruption, and mandibular growth. The delivery of the corrected gene or mutation safely back to humans still remains as a major roadblock. Advances are being made, but progress has been slow. Once the technical aspects of gene delivery are solved, it will change the way that we practice orthodontics.

DR. KEIM What advances have been made in the application of vibratory forces in enhanced tooth movement?

DR. NANDA Animal and clinical human studies are in progress examining the role of vibration on orthodontic tooth movement. Early results are clear that vibration does not cause any negative side effects to the teeth or periodontium. However, more work is needed to elucidate its role in regulating the rate of orthodontic tooth movement.

DR. KEIM Your department has probably produced more orthodontic educators and researchers than any other. What's your secret?

DR. NANDA We are extremely proud of our record in this arena. Since the start of our program, we have concentrated on selecting residents who show evidence or desire to go into research and teaching. We have had the fortune of receiving several National Institutes of Health training grants to help direct research and support our PhD and master's residents. Currently, almost 25% of our graduates are in some form of teaching position, from part-time to program director and/or department head. Again, success of an orthodontic program can be measured by many methods; our success is because of the quality and success of our graduates and faculty.

REFERENCES

1. Nanda, R.: Protraction of maxilla in rhesus monkeys by controlled forces, *Am. J. Orthod.* 74:121-141, 1978.
2. Nanda, R.: Biomechanical and clinical considerations of a modified protraction headgear, *Am. J. Orthod.* 78:125-139, 1980.
3. Nanda, R. and Hickory, W.: Zygomaticomaxillary suture adaptations incident to anteriorly directed forces in rhesus monkeys, *Angle Orthod.* 54:199-210, 1984.
4. Tanne, K.; Matsubara, S.; and Sakuda, M.: Locations of the center of resistance of the nasomaxillary complex in a three-dimensional finite element model, *Br. J. Orthod.* 22:227-232, 1995.
5. Sugawara, J. and Mitani, H.: Facial growth of skeletal Class III malocclusion and the effects, limitations, and long-term dentofacial adaptations to chin cup therapy, *Semin. Orthod.* 3:244-254, 1997.
6. Wendell, P.D. and Nanda, R.: The effects of chin cup therapy on the mandible: A longitudinal study, *Am. J. Orthod.* 87:265-274, 1985.
7. Ritucci, R. and Nanda, R.: The effect of chin cup therapy on the growth and development of the cranial base and midface, *Am. J. Orthod.* 90:475-484, 1986.
8. Burstone, C.J. and Koenig, H.A.: Creative wire bending: The force system from step and V bends, *Am. J. Orthod.* 93:59-67, 1988.
9. Burstone, C.J. and Koenig, H.A.: Force system from an ideal arch, *Am. J. Orthod.* 65:270-289, 1974.
10. Deluke, M.; Uribe, F.; and Nanda, R.: Correction of a canted lower incisal plane, *J. Clin. Orthod.* 40:555-559, 2006.
11. Palacios, P.; Uribe, F.; and Nanda, R.: Correction of an asymmetrical Class II malocclusion using predictable force systems, *J. Clin. Orthod.* 41:211-216, 2007.
12. Nagasaka, H.; Sugawara, J.; Kawamura, H.; and Nanda, R.: "Surgery first" skeletal Class III correction using the Skeletal Anchorage System, *J. Clin. Orthod.* 43:97-105, 2009.
13. Villegas, C.; Uribe, F.; Sugawara, J.; and Nanda, R.: Expedited correction of significant dentofacial asymmetry using a "surgery first" approach, *J. Clin. Orthod.* 44:97-103, 2010.
14. Costopoulos, G. and Nanda, R.: An evaluation of root resorption incident to orthodontic intrusion, *Am. J. Orthod.* 109:543-548, 1996.
15. Sugawara, J.; Kanzaki, R.; Takahashi, I.; Nagasaka, H.; and Nanda, R.: Distal movement of maxillary molars in non-growing patients with the skeletal anchorage system, *Am. J. Orthod.* 129:723-733, 2006.
16. Havens, B.; Wadhwa, S.; and Nanda, R.: Orthodontics in the year 2047: Genetically driven treatment plans, *J. Clin. Orthod.* 41:549-556, 2007.